



## Summary Feedback

### ST1 – ST4 Teaching Programme 2024

#### DKT FRCR 2B Practice Viva (Session 74)

#### THE POT-POURRI OF FRCR VIVA CASES

#### Top Tips, Differentials, "A to ZEE" & More ! (Part 13)

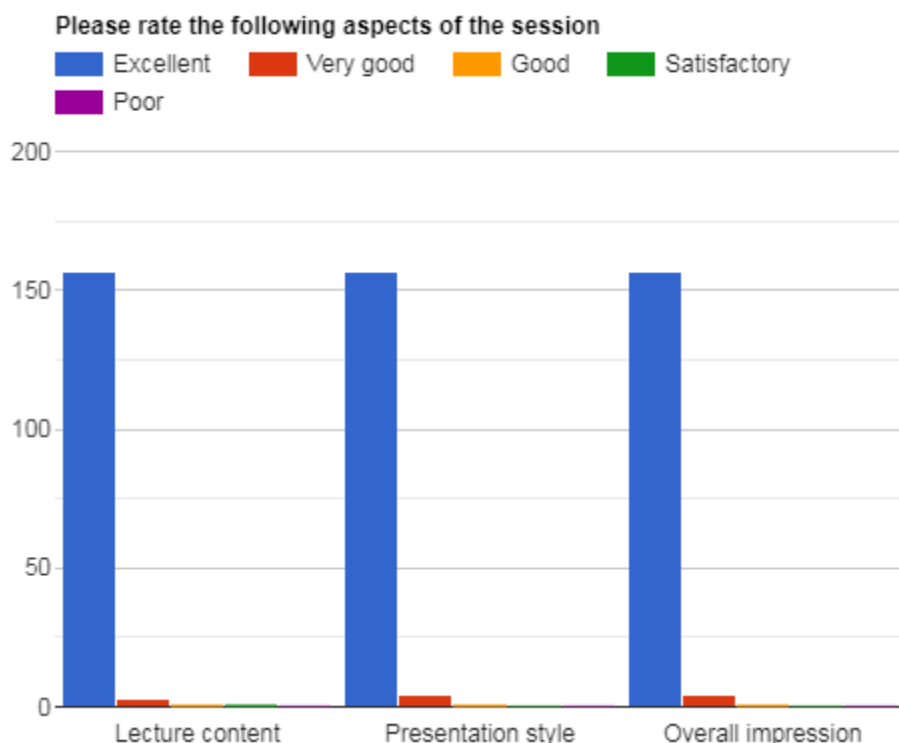
(8<sup>th</sup> August 2024)

Delivered By:

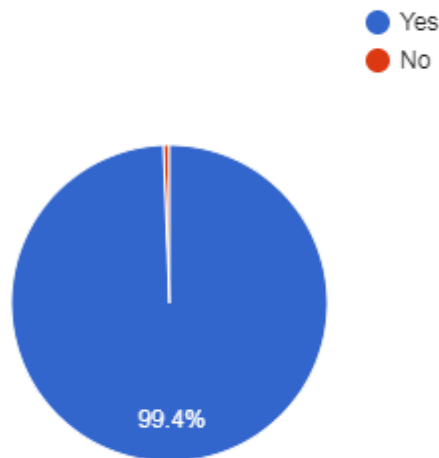
(Sami Khan)

#### Summary Points:

- ST1-ST4 teaching programme 2024 – FRCR 2B Practice Viva Session 74: 2.5 hours teaching time
- Total Attendees: 456 from 36 Countries (Algeria, Australia, Bahrain, Bangladesh, Canada, China, Dominica, Egypt, Ghana, Hong Kong, India, Indonesia, Iran, Iraq, Jordan, Kenya, Kuwait, Libya, Malaysia, Maldives, Mauritius, Nepal, Nigeria, Oman, Pakistan, Qatar, Saudi Arabia, South Africa, Sri Lanka, Sudan, Türkiye, UAE, UK, Yemen, Zambia, Zimbabwe).
- Total feedback received from 162 participants



Did you find it useful  
162 responses



## Testimonials

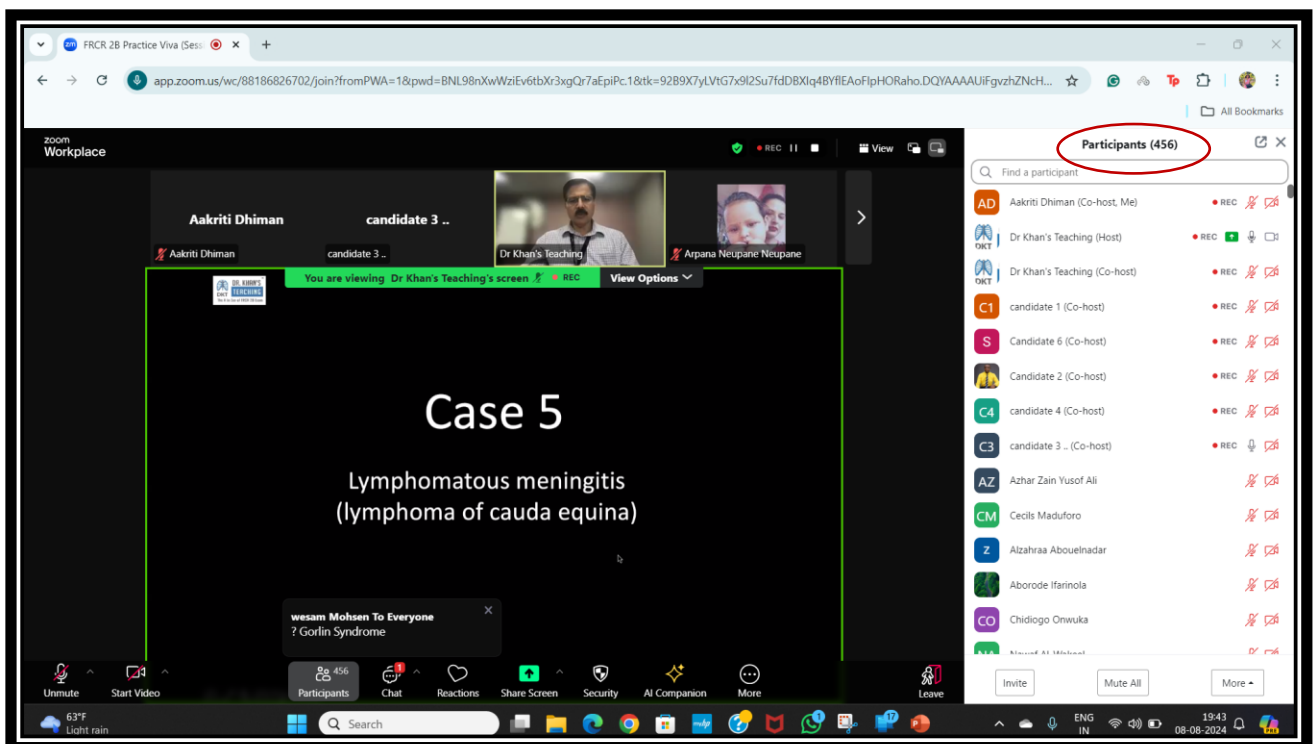
- Really fantastic weekly teaching that I've been trying to attend regularly. It is really helping to build my confidence for the upcoming 2B exam, with great pearls of knowledge along the way. Thank you so much! (UK).
- Great variety of cases that really got me thinking- excellent preparation for the 2B exam. Thank you so much! (UK).
- Dr. Khan's tips and points on how to approach clinical and exam cases and his guidance and orientations for candidates, what to do and what not to do in addition to the marvelous cases and the brilliant theoretical information were valuable (Yemen).
- Thank you sir for your selfless efforts and teaching us radiology in the best way. I am learning a lot from the sessions (UK).
- Very interesting cases, useful to understand how imaging should be presented (UK).
- Thank you so much sir for all what you are doing. It's really a privilege to be able to attend your highly valuable sessions (Egypt).
- Very lucky to be in your session with your special teaching pathway. God bless you sir (Yemen).
- Beautiful session, interesting cases and constructive feedback (Algeria).
- We are most grateful for the Dr.Khan's teaching for invaluable sessions (Iraq).
- Excellent cases and teaching points. Extremely grateful to Sir (UAE).
- Dr Khan's way of teaching was most useful. He is very calm (Kuwait).
- Excellent lecture with good exam oriented topics (India).
- The diversity of topics were useful (Malaysia).
- Very helpful for exam prep (Pakistan).
- Showing daily based cases and diagnosis was useful (Saudi Arabia).
- Rare cases being shown which can be exam cases (Zimbabwe).
- Good explanation and learning... viva questions are said (India).
- Dr Khan is a wonderful teacher, my role model to be honest (Egypt).

## DKT FRCR 2B Practice Viva (Session 74) THE POT-POURRI OF FRCR VIVA CASES - Top Tips, Differentials, "A to ZEE" & More ! (Part 13)

- Cases and discussion was useful (Egypt).
- All of it was highly useful & valuable (Egypt).
- Amazing cases and the best explanations by Sami sir (India).
- Good links between cases and clinical reasoning with Chapman (UK).
- Variety of cases and going through differentials were useful (UK).
- 'Rare and common cases were shown together' was most useful (Türkiye).
- Conceptual part was most useful. Awesome (India).
- The differential diagnosis and the explanations provided to exclude them was most useful (UK).
- Brilliant cases and very patient explanation (UK).
- Wonderful cases (Maldives).
- Excellent cases (India).
- Very well time management with spot on feedback (Pakistan).
- Nice cases (Pakistan).
- Case discussion was useful (Qatar).
- Feedback by the moderator was most useful (UK).
- Actually all aspects and cases was great (Iraq).
- Interesting cases. Pertinent to my practice (UAE).
- Cases and teaching was useful (Saudi Arabia).
- Nice explanation for arthritis approach (Kuwait).
- Perfect cases and explanation (Türkiye).
- Very good cases (Egypt)
- Excellent session (Saudi Arabia).
- Dr Khan's explanations were most useful (Pakistan).
- Superb session (India).
- Excellent teaching as always (Nigeria).
- Great material for the future radiologist (Zimbabwe).
- Very good (China).
- Interesting case explanations (UK).
- Excellent cases and description (Sri Lanka).
- It was perfect (UAE).
- Great cases (South Africa).
- Selection of cases and explanation regarding differentials were useful (Pakistan).
- Wonderful session. Interesting cases (Sri Lanka).
- Different cases and presentations for venous infarction was useful (UK).
- The cases are top notch for practice, thank you (Zimbabwe).
- Satisfaction of search avoidance!, cases with incidental findings were useful (UK).
- Good mixture of cases with differential lists (UK).
- The literature on the case and the range of cases was useful (Ghana).
- Great session (Malaysia).
- Dr Khan's specific case feedback was useful (UK).
- The teaching session was useful (Nigeria).
- Excellent cases and explanation (UK).
- Nice collection of different cases (Sri Lanka).
- The patient delivery of so much information was useful (Nigeria).

# DKT FRCR 2B Practice Viva (Session 74) THE POT-POURRI OF FRCR VIVA CASES - Top Tips, Differentials, "A to ZEE" & More ! (Part 13)

- Excellent teaching (China).
- Excellent teaching (UK).
- Brilliant session (Iraq).
- Amazing session (UK).
- It was perfect (UAE).
- Very helpful session (Malaysia).
- Excellent as usual (Zimbabwe).
- Brilliant as usual (UAE).
- Brilliant session (Pakistan).
- Very educative (UK).
- Awesome session (India).
- Outstanding (Saudi Arabia).
- Very informative (UAE).
- Exceptional (Pakistan).
- Excellent teaching session (Algeria).
- Great presentation (South Africa).
- Excellent teaching session (Pakistan).
- Great and very informative session (UK).
- Woow (Egypt).
- Excellent, will attend in future definitely (UK).
- Great content (India).



# DKT FRCR 2B Practice Viva (Session 74) THE POT-POURRI OF FRCR VIVA CASES - Top Tips, Differentials, "A to ZEE" & More ! (Part 13)

The screenshot shows a Zoom meeting interface. The main window displays a presentation slide titled "TALO-CALCANEAL COALITION". The slide features a grid of 12 axial CT scans of the ankle, arranged in two rows of six. The top row is labeled "ANTERIOR FACET" and "MIDDLE FACET", and the bottom row is labeled "POSTERIOR FACET". A green box highlights the presentation area. The Zoom meeting controls at the bottom show 372 participants. A chat window on the right side of the screen contains the following messages:

- waseem sajjad 06:42 PM: this case which one?
- dr aisha talib to Everyone 06:42 PM: talonavicular,talocalcaneal
- Mohamed Dam to Everyone 06:42 PM: Calceno navicular
- dr aisha talib to Everyone 06:42 PM: thia was talonavicular.
- waseem sajjad to Everyone 06:43 PM: no, it is calcaneo-navicular
- Dr F to Everyone 06:45 PM: sir how can you differentiate this from talocalcaneal subluxation?

The system tray at the bottom shows the date as 08-08-2024 and the time as 18:49.

The screenshot shows a Zoom meeting interface. The main window displays a presentation slide titled "Clinically stroke". The slide features three axial CT scans of the brain. The first two scans are standard axial views, and the third is a high-density scan. A green box highlights the presentation area. The Zoom meeting controls at the bottom show 431 participants. A chat window on the right side of the screen contains the following messages:

- Dr. Randa Hamood

The system tray at the bottom shows the date as 08-08-2024 and the time as 20:24.

-----XX-----XX-----